

Ovarian ectopic pregnancy: a review article

Meena P.¹, Bhojwani P², Verma G. S.³

¹Dr. Pragati Meena, ²Dr. Poonam Bhojwani, ³Dr. Gajendra Singh Verma, all authors are affiliated with Department of Obstetrics & Gynecology, NIMS Medical College and Hospital, Shobha Nagar, Delhi Highway Jaipur, Rajasthan, India.

Corresponding Author: Dr. Poonam Bhojwani, Email: drpragati02@gmail.com

Abstract

Ectopic pregnancy is a major health issue in reproductive age group female. Incidence of primary ovarian ectopic pregnancy as mentioned in literature of India is variable from 0.001% to 0.014% of normal pregnancies. Only 0.15% to 3.0% of all ectopic pregnancy occurs in ovary and it is 2nd most common site of ectopic pregnancy after fallopian tube. Annual incidence of extra uterine cavity pregnancy is rising over past 3 yrs. The aim of our present study is to find out the incidence of ovarian ectopic pregnancy, role of USG in pre-operative diagnosis and risk factors, feasibility of conservative management with medical method or conservative management e.g. minimal invasive surgery in developing countries like India. We analysed the incidence, management of ovarian pregnancy & reviewed the literature, risk factors and clinical presentation of ovarian ectopic pregnancies managed at NIMS Medical College and Hospital Jaipur. According to Spielberg criteria, it is a diagnostic challenge to obstetrician. Diagnosis of ectopic pregnancy can be missed radiologically and intraoperatively. It should be suspected in patients presented with ruptured ectopic pregnancy, ultrasound features suggestive of normal bilateral fallopian tube with hemo peritoneum with breached ovarian surface. Conservative surgical approach is preferred, nowadays medical management is preferred for unruptured ectopic pregnancy. Confirmation of ovarian pregnancy done only after histopathological report. Nowadays medical management with single dose of Methotrexate is very successful for unruptured ovarian pregnancy.

Keywords- Ectopic pregnancy, Laparotomy, Salpingoophorectomy, Methotrexate

Introduction

The incidence of ectopic pregnancy is 1.2-1.4%. Incidence of primary ovarian ectopic pregnancy is, as mentioned in literature of India is variable from 0.001% to 0.014% of normal pregnancies. Only 0.15% to 3.0% of all ectopic pregnancy occurs in ovary and it is 2nd most common site of ectopic pregnancy after fallopian tube [1].

Extra uterine pregnancy or ectopic ovarian pregnancy a Greek word originated from "EKTOPOS" which means out of place. Ectopic refers to implantation of blastocyst outside of uterine cavity [1]. Primary ovarian ectopic pregnancy is very rare clinical presentation of extra uterine pregnancy & a life threatening emergency also if not diagnosed timely. Fallopian tube is most common site of ectopic pregnancy, comprises to 95% of total ectopic pregnancies. Incidence increasing with ART procedures and IUCD insertion. Ovarian pregnancy is gestational sac implantation in the ovary. First case of

ovarian pregnancy is reported by St. Maurice in 1689 [2]. Its diagnosis is very difficult & based on clinical diagnosis, intra operative finding and on histopathology examination report. Definite management of ruptured ovarian pregnancy is surgical. Approximately 75% pregnancies terminate in early gestation, 12.5% patients terminate in the second trimester & 12.5% patients reached till term. Ovarian pregnancy in 1624, suggested first by Mercerus [3,4].

Incidence of ectopic pregnancy is-

1. Tubal pregnancy- 90-95.5%
2. Ovary-1.5- 3%
3. Abdomen-1.3%
4. Cervical -0.15%
5. Heterotopic 1-2%
6. Caesarean -6%
7. Interstitial -2.5%

Manuscript received: 08th December 2017

Reviewed: 14th December 2017

Author Corrected: 20th December 2017

Accepted for Publication: 31st December 2017

Case Report

A 28 years old female, presented with 6 weeks amenorrhea with severe right sided lower abdominal pain with no history of vaginal bleeding came to our hospital emergency corresponds to 6 weeks and 3 days of gestational period. According to her, his previous menstrual history was normal. There was no history of PID, ART procedure, Tuberculosis and any Infertility treatment. On her examination, her vitals were BP-90/60 mm of Hg, PR-110 /min, clinical features suggestive of haemorrhagic shock were present. On her P/Aexamination - soft distension was present and tenderness present in RIF. P/V examination revealed – uterus mobile and non-tender, cervical motion tenderness present, 2.8x2.8 cm adnexal mass felt in right fornix. Patient investigated, her UPT +ve, Hb% 8gm, TLC 10, 600/cumm, rest hemogram was normal, USG findings Shows Empty uterine cavity & bulky ET-19 mm , 2.8x2.8cm right adnexal mass seen without fetal pole, free fluid present in POD.

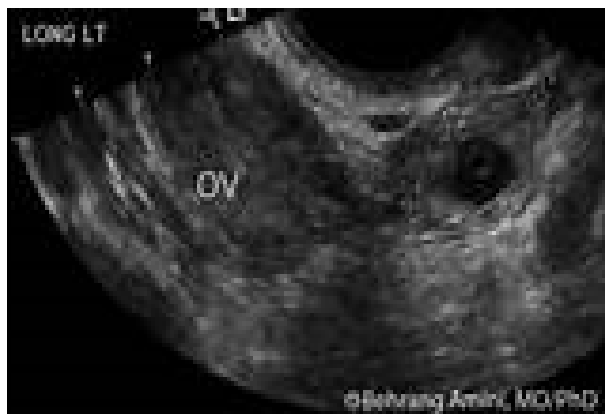

Image No-1: Ultrasound showing ovarian ectopic pregnancy

Our provisional diagnosis was ruptured ectopic pregnancy was made & patient was prepared for laparotomy, her intra operative findings were-

- ✓ Hemoperitoneum of 200 cc was present
- ✓ Uterus was bulky
- ✓ B/L fallopian tubes normal & left ovary normal
- ✓ Rt ovary enlarged by a 2.8 × 2.8 cm sized adnexal mass in situ which visible as bluish red color with oozing from breached ovarian surface.

Right salpingo - oophorectomy done and Left fallopian tubal ligation done by modified pomeroys method and tissue sent for histopathological examination. Her postoperative period was uneventful. Her histopathology report shows corpus luteum with trophoblastic villi in the ovarian tissue. Histopathological report of her D&C tissue shows absence of villous or fetal tissue.

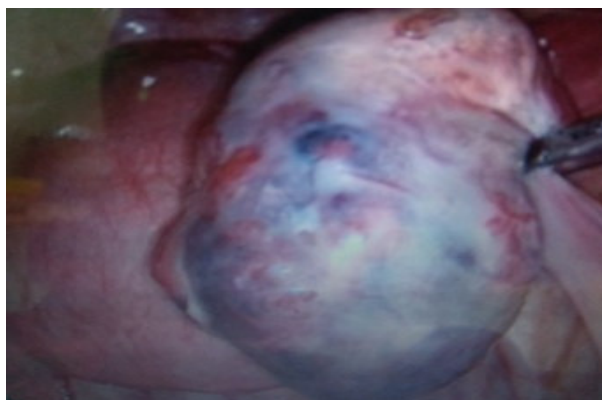

Image No-2: Intraoperative finding showing ovarian pregnancy

Review Article

Histopathology report & her intra operative findings were satisfied with the Spielberg criteria. Her immediate and long term postoperative course was uneventful. Patient followed up in OPD after 1 week of surgery. Her serial β hcg was on D5 - 500miu/ml, D12 -30miu/ml, D19- undetectable.

Discussion and Review of Literature- Clinical presentation of ovarian ectopic pregnancy is variable and it is a life-threatening emergency. Etiology of ovarian ectopic pregnancy still remains obscure. A study done by Goyal et. al concluded that incidence of ovarian pregnancy is 4.8% of all pregnancies. 94% patients diagnosed in early first trimester, 11% cases diagnosed preoperatively [4,5]. Incidence increases with ART procedures [due to increase progesterone from corpus luteum, ovarian hypervascularity due to hyperstimulation], PID, previous pelvic surgery, PCOD, fibroid uterus. IUCD is found in 15-32% of patients of non ovarian ectopic pregnancy and 60-92% of patient of ovarian ectopic pregnancy. Grimes et. al studied 24 cases of ovarian pregnancy & concluded that $\geq 50\%$ cases had infertility or history of failed ART [5,6].

Cigarette smoking interferes with tubal motility and ovum pickup. There is usually delay in diagnosis because of Gestation sac of ovarian ectopic pregnancy in ultrasound mimics to haemorrhagic cyst of ovary, corpusluteal cyst and endometrioma of ovary. Diagnosis confirmed by TVS and CT scan. Ovarian pregnancy carries higher risk of morbidity and mortality than tubal pregnancies because ovarian pregnancy located at the most vascularised site of female pelvis. Uterine artery and ovarian anastomosis of blood vessels eroded by developing chorionic villi, that leads to severe haemorrhage and patient may go into haemorrhagic shock [7,8].

Ovarian ectopic pregnancies diagnosed intraoperatively & histo-pathologically except few exceptions according to **Spielberg criteria**. Ovarian ectopic pregnancy should be differentiated from ampullary /infundibular tubal pregnancy, in these cases ovaries may involve secondarily after tubal abortion or rupture [9].

Criteria includes:

1. Gestation sac should occupy the normal position of the ovary.
2. Gestation sac and uterus connected with each other by utero-ovarian ligament.
3. Affected side fallopian tube with its fimbria should be intact and separate from ovary.
4. Ovarian tissue (tunica albuginea) must be present in the specimen or in the wall of gestational sac.
5. Empty uterine cavity and evidence of amniotic cavity within follicle.

3D ultrasound (TVS) help to differentiate from haemorrhagic corpus luteal cyst (8). Diagnostic features of ovarian pregnancy are-

Sensitivity is 85%-92% and specificity is 99.98%

1. Double echogenic ring found within hypoechoic latero-uterine mass & echogenicity of ring is more than ovary itself (in homogenous mass). Wide echogenic ring with an internal echolucent areas on superficial ovarian surface are also found.
2. Gestational sac found adjacent to the ovary.
3. All around mass follicles & corpus luteum is present as a part of ovarian cortex.
4. Empty uterine cavity & free fluid in peritoneal cavity (mild fluid in pouch of Douglas is physiological)
5. Ovarian ectopic pregnancy will move with ovary on pressure applied with transvaginal probe.

Gestation sac visualized by trans-abdominal scan at β -hCG discriminatory zone ≥ 6500 miu/ml in 1981. Discriminatory zone for Transvaginal ultrasound upto 1000 to 2000 miu/ml

Com shock et. al studied ultrasonographic appearance of ovarian ectopic pregnancy and they concluded ovarian pregnancy is rarely identified correctly by sonography and it is even very difficult to diagnose intra operatively. [9,10].

Heterotopic pregnancy is Ectopic pregnancy coexist with an intrauterine pregnancy but it is very rare with incidence 1/40000, diagnosis is very difficult. It is common with assisted conception.

Benauer et. al suggested that transducer frequency from 7MHZ to 10MHZ is helpful in improving diagnostic accuracy [10] ovarian ectopic pregnancy classified into two types –

Review Article

1. Intrafollicular pregnancy- In this ovum trapped inside the follicle, mature ovum not picked up or expelled from its follicle. Sperm fertilize the egg after entering into follicle various theories are given for explanation

- Hormonal causes
- Thickened tunica albuginea of the ovary
- Defect in ovum pick up due to inadequate fimbria on ovarian surface

2. Extra follicular pregnancy-mature ovum fertilized outside of ovary, implant on ovarian surface because of endometrial decidual reaction.

Few hypotheses suggested inflammatory thickened tunica albuginea and malfunctioning of tubes, interference of release of mature ovum from follicle. The sign and symptom of primary ovarian pregnancy are very similar to tubal ectopic pregnancy. Very difficult to differentiate clinically from chocolate cyst, haemorrhagic cyst, tubal pregnancy.

Trophoblastic cells invade the ovarian tissue on 6th day, followed by the invasion of the ovarian artery. Although ovarian pregnancies rupture by the 40th gestational day, reports of those progressing into the 3rd trimester even to live births have been established.

Most of primary ectopic pregnancy usually ruptured in first trimester of pregnancy. Recurrent ectopic pregnancy is not reported yet, in contrast to tubal pregnancy, 15% recurrence noted in primigravida patients. A study done by Savita et al. according to them out of 104 patients only 94 patients had ectopic proved by histopathology and remaining had either haemorrhagic cyst or corpus luteal hematoma. out of 94 patients only four had ovarian pregnancy who fulfilled Spiegelberg criteria. Future fertility after surgery is unaffected [10].

Our retrospective cross – sectional study on ovarian pregnancies at NIMS Medical college & hospital Jaipur, we studied risk factor, incidence, diagnosis and management of ovarian pregnancy.

Table No-1: Risk factor for ovarian pregnancy.

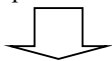
S.No.	Age	POG-weeks	O/H	Past history	USG finding	Management
1	20	9 wk	G4P2L2A1	IUCD-3yr	FF in POD	Excision of sac & B/L salpingectomy
2	23	-	G1	1*infertility	FF in POD	Excision of sac & B/L salpingectomy
3	24	7wk	G5P2L2A2	IUCD-2yr	Bhcg-2000	Excision of sac & B/L salpingectomy
4	25	Nil	P3L3	IUCD-5yr	4×4cm, adnexal	Rt oophorectomy
5	24	34wk	G4P3L2	MTP	Placenta previa	Laprotomy with Excision of placenta delivery of baby and oophorectomy
6	33	9wk	G3P1L1A1	--	FF in POD, βhcg-1800	Excision of sac , repair
7	24	8wk	G2A1	--	Lt adnexal mass, FF +	Lt oophorectomy
8	35	7wk	G4P2L3	IUCD-4yr	Lt ovarian G. Sac, βhcg-2000	Excision of sac
9	24	8wk	G1	Infertility	FF in POD	Excision of sac
10	31	Nil	P3L3	--	Rt adnexal mass βhcg-3000	Excision of sac & repair

A study done by Savita et al concluded out of 4 patient 3 patient had history of risk factor like IUCD was present [11].

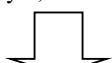Management- Expectant Management- Success rate is 48%-100%.

Inclusion criteria –

- Asymptomatic women with stable vitals
- B-hCG < 1000 mIU/ml
- Ultrasound findings – Size \leq 2cm and GA < 6 weeks, Cardiac activity absent, Yolk sac and fetal pole also absent, Free fluid in pouch of Douglas < 100CC.
- Serum progesterone level < 3.1 ng/ml
- Cooperative patient willing for follow up



These patients followed twice weekly on Day 3, 7.



If β -hcg fall > 50% within a week, continue expectant management

If β -hcg fall < 50% within a week, consider medical /surgical management.

It is most useful when initial β -hCG level is \leq 1000 IU/ml with unruptured ectopic pregnancy. Success rate is between 50-80%. According to one prospective observational study, in which 118 patients are on expectant management out of them 88% recovered successfully. They had β -hCG \leq 200 mIU/ml and patients with β -hCG level \geq 2000 mIU/ml only 26% recovered. Favourable factors for success of expectant management are serum β -hCG level \leq 200, gestational age \leq 6 weeks & progesterone level below 10 nmol/L. Expectant management to be stopped if the patient is having if the β -hCG level increases or Persistently increasing abdominal pain. To avoid rupture of ectopic pregnancy, avoid vigorous physical activity sexual activity & pelvic examination.

Medical Management- Mittal et. al first time used injection methotrexate directly into gestational sac of ovary [12]. Kudo et. al reported first successful use of methotrexate in ovarian pregnancy [13]. Gabbur et al. Done a retrospective analysis on MTX use in unruptured ovarian ectopic and concluded that after single MTX injection on Day 7 β -hcg levels only, predict need of surgery or successful treatment not Day 4 β hcg level [13,14] Patient selection is very important. Methotrexate is antagonist of folic acid that impairs cell replication & DNA synthesis. In 1982, Methotrexate first time used for medical management and its mode of action is kill rapidly dividing cytotrophoblasts cells at the site of implantation [15].

Table No-2: Contraindication of Methotrexate treatment in ectopic pregnancy

Absolute	Relative
i. Hypersensitivity	i. B-hCG > 5000 mIU/ml
ii. Thrombocytopenia (< 1 lac/ μ l)	ii. Ectopic mass > 4 cm
iii. Liver dysfunction > 2 fold. Alcoholic liver disorders.	iii. Fetal cardiac activity present
iv. Pulmonary and peptic ulcer disease	iv. Poor complaint patient
v. Hematological dysfunction with bone marrow depression. TLC < 1500/ μ l	
vi. Heterotopic pregnancy	
vii. Ruptured ectopic pregnancy	
viii. Lactating mothers	
ix. Moderate to severe anemia	
creatinine clearance < 50 mL per minute per 1.73 m ²	

Patient should instruct to stop taking prenatal vitamins, Alcohol, nonsteroidal anti-inflammatory drugs & avoid excessive sunlight (to avoid MTX induced dermatitis) and folate supplementation, as folate will counteract action of injection methotrexate. Rh status of patient must be known to determine further need of immunoglobulin therapy in Rh negative patient. A meta-analysis on single and multiple dose regimens done by Barnhart et al. They concluded multidose regimen is more effective (90%) than single dose (80%) [13,14,15].

If β hCG is \geq 5000 treatment failure rate is 40%. If 15% decrease occurs b/w Day 4 and Day 7, β -hCG levels monitored weekly till reach zero. This will take at least five to seven weeks.

Review Article

Levin et al. done a study and concluded, out of 69 women of study group 45 patient was treated successfully with single dose of injection methotrexate [13].

Predictors of successful medical treatment before single dose of methotrexate good are-

If β -hCG level \leq 1600 iu/ml and increase \leq 14% , in a day or 24 hr.

Single dose regimen associated with least side effects.

Table No-3: Single dose of methotrexate treatment protocol.

	0	4	7
1. Investigations	Bhcg CBC ABORh LFT RFT	Bhcg	Bhcg
2. Medical management	Methotrexate in dose of 50mg/m ² of body surface area is given by IM route	Methotrexate in dose of 50mg/m ² of body surface area is given by IM route	i. If Decrease in β hcg >15% between from day 4 to day 7. Monitor β hcg weekly till zero. ii. If β hcg decrease < 15% between day 4 to day 7 give methotrexate

Two dose regimes of methotrexate of ectopic pregnancy-

Branhart was only one who first described Double dose regimen. Hossam et al concluded that double dose protocol is better than single dose regimen [16,17].

Table No-4: Multiple dose of methotrexate treatment protocol

	0	4	7	11	14
Investigation	CBC Abo, Rh LFT RFT β hcg	Bhcg	Bhcg	Bhcg	Bhcg
Medical management	Methotrexate in dose of 50mg/m ² of body surface area is given by IM route.	Methotrexate in dose of 50mg/m ² of body surface area is given by IM route.	If Decrease in β hcg >15% between from day 4 to day 7. Monitor β hcg weekly till zero. If β hcg decrease < 15% between day 4 to day 7. give methotrexate.	If Decrease in β hcg >15% between from day 7 to day 11. Monitor β hcg weekly till zero. If β hcg decrease < 15% between day 7 to day 11. give methotrexate	If Decrease in β hcg >15% between from day 11 to day 14. Monitor β hcg weekly till zero. If β hcg decrease < 15% between day 11 to day 14 Refer to surgery

Multiple dose regime of methotrexate in ectopic pregnancy- Krik et al concluded that multiple dose regimen is more effective than single and double dose protocol with sensitivity 94%, specificity 86% [1,17,18]. Success rate of treatment with β - hCG \leq 1000 mIU/ml is 87%. Failure rate is 40% with level \geq 5000 mIU/ml.

Review Article

Surgical Management- Primary management of Ovarian ectopic pregnancy is surgical. According to 3 prospective randomized trial laparoscopic approach is superior then laparotomy in view of less blood loss & pain, shorter hospital stays and there is no significant difference in recurrence, subsequent intrauterine pregnancy [18,19]. Laparoscopic surgery has become preferred method & gold standard nowadays. Conservative surgical technique like ovarian wedge resection, nucleation are also in trend now days. 80% cases managed by conservative management and radical oophorectomy done in 13% cases only. John et al. Was performed first laparotomy for ovarian ectopic pregnancy in 1759. In 1884 Robert et al. Ligated bleeding blood vessels first time during laparotomy [4]. Shapiro and Adler introduced first time a laparoscopic approach in 1973 [20,21]. According to Cochrane review 2007, there is no significant difference b/w systematic methotrexate and conservative surgery if β -hCG level ≤ 1500 mIU/ml

Corpus luteal cystectomy for trophoblast, curettage of trophoblast by coagulation and hemostatic suture of the bed. These are totally conservative surgeries. In case of advanced ectopic pregnancy oophorectomy or ovariectomy [22,23,24]. Recurrence of ovarian pregnancy in literature till now. Only single case reported has been reported in contrast to tubal ectopic pregnancy recurrence rate is up to 15% [25-30].

Conclusion and Perspective- According to Spielberg criteria, it is a diagnostic challenge to obstetrician. diagnosis can be missed radiologically, intraoperatively. Ovarian pregnancy can occur even in Nulliparous female without risk factors like IUCD, PID, ART. Now days Medical management with single dose of Methotrexate is very successful for unruptured ovarian pregnancy. Should be suspected in patients presented with ruptured ectopic pregnancy, ultrasound features suggestive of normal fallopian tube with hemoperitoneum with breached ovarian surface. Conservative surgical approach is preferred. Confirmation of ovarian pregnancy done only after histo-pathological report.

Funding: Nil, **Conflict of interest:** Nil

Permission from IRB: Yes

References

- Joseph RJ, Irvine LM. Ovarian ectopic pregnancy: aetiology, diagnosis, and challenges in surgical management. *J Obstet Gynaecol.* 2012 Jul; 32 (5):472-4. doi: 10.3109/01443615.2012.673039.
- Mehmood SA, Thomas JA. Primary ectopic ovarian pregnancy (report of three cases). *J Postgrad Med* 1985; 31: 219.
- Rana P, Kazmi I, Singh R, Afzal M, Al-Abbasi FA, Aseeri A, Singh R, Khan R, Anwar F. Ectopic pregnancy: a review. *Arch Gynecol Obstet.* 2013 Oct; 288 (4): 747-57. doi:10.1007/s00404-013-2929-2. Epub 2013 Jun 21.
- Krik E, Bourne T. Ectopic pregnancy. *Obstet gynecol Reprod Med* 2011;21(7):207-211,2011.
- Goyal Lajya Devi, Tondon Rimpay, Goel Poonam and Sehgal Alka. Ovarian ectopic pregnancy: A 10 years' experience and review of literature. *Iran J Reprod Med.* 2014 December; 12(12): 825–830.
- Fritz MA, Speroff L. Clinical gynecologic endocrinology and infertility, 8th edn. Wolters Kluwer Health/ Lippincott Williams & Wilkins, Philadelphia. 2011.
- Hallatt JG. Primary ovarian pregnancy: a report of twenty-five cases. *Am J Obstet Gynecol.* 1982;143:55–60. PMID: 7081312. doi.org/10.1016/0002-9378(90)90685-Z.
- Panelli Danielle M, H. Phillips Catherine, Brady Paula C. Incidence, diagnosis and management of tubal and nontubal ectopic pregnancies: a review. *Fertility Research and Practice* 2015; 1:15,2015. DOI:10.1186/s40738-015-0008.
- Vanitha N Sivalingam, W Colin Duncan; Emma Kirk, Lucy A Shephard, Andrew W Horne. Diagnosis and Management of Ectopic Pregnancy. *J Fam Plann Reprod Health Care.* 2011; 37(4): 231-240,2011. doi:10.1136/jfprhc-2011-0073.
- Comstock C, Huston K, Lee W. The ultrasonographic appearance of ovarian ectopic pregnancies. *Obstet Gynecol.* 2005 Jan;105(1):42-5.
- Chang FW, Chen CH, Liu JY. Early diagnosis of ovarian pregnancy by ultrasound. *Int J Gynecol Obstet.* 2004; 85:186–187.
- Juan YC, Wang PH, Chen CH, Ma PC, Liu WM. Successful treatment of ovarian pregnancy with laparoscopy-assisted local injection of etoposide. *Fertil Steril.* 2008;90:1200

Review Article

13. Mittal S, Dadhwal V, Baurasi P. Successful medical management of ovarian pregnancy. *Int J Gynecol Obstet.* 2003;80:309–310.
14. Buster JE, Carson SA. Ectopic pregnancy: new advances in diagnosis and treatment. *Curr Opin Obstet Gynecol.* 1995 Jun;7(3):168-76.
15. Gabbur N, Sherer DM, Hellmann M. Do serum beta-human chorionic gonadotropin levels on day 4 following methotrexate treatment of patients with ectopic pregnancy predict successful single-dose therapy? *Am J Perinatol.* 2006. 23:193–196.
16. Barnhart KT, Gosman G, Ashby R, Sammel M. The medical management of ectopic pregnancy: a meta-analysis comparing "single dose" and "multidose" regimens. *Obstet Gynecol.* 2003 Apr;101(4):778-84.
17. Barnhart K, Hummel AC, Sammel MD, Menon S, Jain J, Chakhtoura N. Use of "2-dose" regimen of methotrexate to treat ectopic pregnancy. *Fertil Steril.* 2007 Feb;87(2):250-6. Epub 2006 Nov 13.
18. Hamed HO, Ahmed SR, Alghasham AA. Comparison of double- and single-dose methotrexate protocols for treatment of ectopic pregnancy. *Int J Gynaecol Obstet.* 2012 Jan; 116(1):67-71. doi: 10.1016/j.ijgo.2011.08.009. Epub 2011 Oct 28.
19. Kirk E, Condous G, Van Calster B, Haider Z, Van Huffel S, Timmerman D, Bourne T. A validation of the most commonly used protocol to predict the success of single-dose methotrexate in the treatment of ectopic pregnancy. *Hum Reprod.* 2007 Mar;22(3):858-63. Epub 2006 Nov 6.
20. Bagga R, Suri V, Verma P, Chopra S, Kalra J. Failed Medical Management in Ovarian Pregnancy Despite Favorable Prognostic Factors-A Case Report. *Med Gen Med.* 2006;8:35. PMID:16926774.
21. Habbu J, Read MD. Ovarian pregnancy successfully treated with methotrexate. *J Obstet Gynaecol.* 2006 Aug;26(6):587-8.
22. Shapiro HI, Adler DH. Excision of an ectopic pregnancy through the laparoscope. *Am J Obstet Gynecol.* 1973;117:290-1. PMID: 4269637.
23. Ayakannu T, Rogers J, Wordsworth S, Jayagopal N, Vine S. Conservative laparoscopic approach with systemic medical management of an ovarian ectopic gestation. *J Obstet Gynaecol.* 2007; 27:449–50. <https://doi.org/10.1080/01443610701360009>.
24. Mittal S, Dadhwal V, Baurasi P. Successful medical management of ovarian pregnancy. *Int J Gynaecol Obstet.* 2003 Mar;80(3):309-10.
25. O. Birge, M. M. Erkan, E. G. Ozbey, and D. Arslan. Medical management of an ovarian ectopic pregnancy: a case report. *Journal of Medical Case Reports.* , 2015; vol. 9:1, article no. 774.
26. G. Scutiero, P. Di Gioia, A. Spada, and P. Greco. Primary ovarian pregnancy and its management," *Journal of the Society of Laparo-endoscopic Surgeons.* 2012 ; vol. 16:3,492–494.
27. Y. Koo, H. Choi, K. Im, H. Jung, and Y. Kwon. Pregnancy outcomes after surgical treatment of ovarian pregnancy. *International Journal of Gynecology & Obstetrics.* 2011; vol. 114:;97–100, 2011.
28. Chatburn Luke, Sanghani Reesha, Chatburn Luke, et al. An Alternative Treatment for the Ovarian Ectopic Pregnancy. *J Womens Health Gyn.* 2015; Vol2: 102.
29. Odejinmi F, Rizzuto MI, Macrae R, Olowu O, Hussain M. Diagnosis and laparoscopic management of 12 consecutive cases of ovarian pregnancy and review of literature. *J Minim Invasive Gynecol.* 2009 May-Jun;16(3): 354-9. doi: 10.1016/j.jmig.2009.01.002.
30. Nadarajah S, Sim LN, Loh SF. Laparoscopic management of an ovarian pregnancy. *Singapore Med J.* 2002 Feb;43(2):095-6.

.....

How to cite this article?

Meena P., Bhojwani P, Verma G. S. Ovarian ectopic pregnancy: a review article. *Obs Rev: J obstet Gynecol* 2017;3(4):63-70. doi:10.17511/joog.2017.i04.06.

.....