

## Ovarian Ectopic Pregnancy: Laparoscopic Excision and Ovarian Conservation – Case Report

Gayam S.<sup>1\*</sup>, Rani G.<sup>2</sup>


DOI: <https://doi.org/10.17511/joog.2023.i01.02>

<sup>1\*</sup> Susheela Gayam, Consultant, Department of Obstetrics and Gynaecology, Vijay Marie Hospital, Hyderabad, Telangana, India.

<sup>2</sup> Geeta Rani, Consultant, Department of Obstetrics and Gynaecology, Vijay Marie Hospital, Hyderabad, Telangana, India.

Ovarian pregnancy is a rare type of non-tubal ectopic pregnancy. 27-year-old primigravida presented with 2 months of amenorrhea with right ectopic pregnancy on routine ultrasonography. But then intraoperatively it was found to be ruptured right ovarian ectopic pregnancy. The similar symptomatology of tubal ectopic pregnancy makes preoperative diagnosis of ovarian ectopic pregnancy difficult. Laparoscopy is the standard management method for haemodynamically stable patients with ovarian ectopic pregnancy. Resection of the ovarian ectopic pregnancy and preservation of the ovary is the mainstay of management in ovarian ectopic pregnancies.

**Keywords:** Ovarian Pregnancy, Laparoscopic Excision, Ovarian Conservation, Histopathology

Corresponding Author	How to Cite this Article	To Browse
Susheela Gayam, Consultant, Department of Obstetrics and Gynaecology, Vijay Marie Hospital, Hyderabad, Telangana, India. Email: <a href="mailto:sushgayam@yahoo.com">sushgayam@yahoo.com</a>	Susheela Gayam, Geeta Rani, Ovarian Ectopic Pregnancy: Laparoscopic Excision and Ovarian Conservation – Case Report. Obs Gyne Review J Obstet Gynecol. 2023;9(1):5-8. Available From <a href="https://obstetrics.medresearch.in/index.php/joog/article/view/158">https://obstetrics.medresearch.in/index.php/joog/article/view/158</a>	

**Manuscript Received**  
2023-03-07

**Review Round 1**  
2023-03-09

**Review Round 2**  
2023-03-16

**Review Round 3**  
2023-03-23

**Accepted**  
2023-03-30

**Conflict of Interest**  
Nil

**Funding**  
Nil

**Ethical Approval**  
Yes

**Plagiarism X-checker**  
18%

**Note**



© 2023 by Susheela Gayam, Geeta Rani and Published by Siddharth Health Research and Social Welfare Society. This is an Open Access article licensed under a Creative Commons Attribution 4.0 International License <https://creativecommons.org/licenses/by/4.0/> unported [CC BY 4.0].



## Introduction

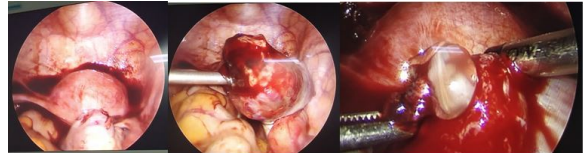
Ovarian pregnancy is a rare form of non-tubal ectopic pregnancy [1]. A definitive diagnosis of ruptured ovarian pregnancy is often difficult and is usually diagnosed at surgery [2]. As the ovarian cortex is thin and lacks elasticity, ovarian pregnancies are usually found to be ruptured [9]. Medical management is usually not feasible as most of them present in a ruptured state. It is recommended that the intact gestational sac be excised and ovarian function is preserved. Thus Laparoscopy with a conservative surgical approach is the management of choice in ovarian pregnancies [3]. The purpose of reporting this case study is to describe a case of ruptured ovarian pregnancy and to study through a review of literature, the specific clinical features, diagnostic criteria and treatment modalities of this specific pathology.

## Case Report

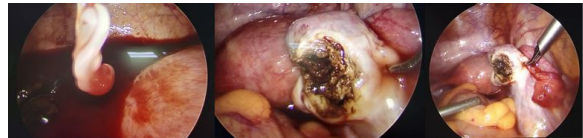A 27-year-old primigravida with 2 months amenorrhea, presented with unremarkable general, systemic clinical examination findings. On bimanual examination uterus and left fornix were normal; right fornix fullness was felt; no cervical motion tenderness present. Transvaginal ultrasonography revealed a cystic lesion in the right adnexa measuring 32 x 33mm with a gestational sac of 6+2 weeks, cardiac activity of 129bpm, no free fluid in POD; uterus measured 59 x 38 x 42mm; endometrium 22mm and normal ovaries, suggesting of right unruptured ectopic pregnancy. S.βhcg was 21,018miu/ml and Hb 9.4gm/ml. The emergency laparoscopy was undertaken in view of the sudden fall in BP. The intraoperative findings included: 300ml of blood in the pelvis (Fig1), uterus, left ovary normal and both fallopian tubes were intact with fimbria and 3x3cm ectopic pregnancy with an intact sac and embryo seen in the right ovary with bleeding from the ruptured site in the ovary (Fig 2, 3).

The ectopic pregnancy with an intact sac was excised and the bleeding points on the ovary were cauterised using bipolar diathermy (Fig 4,5,6).

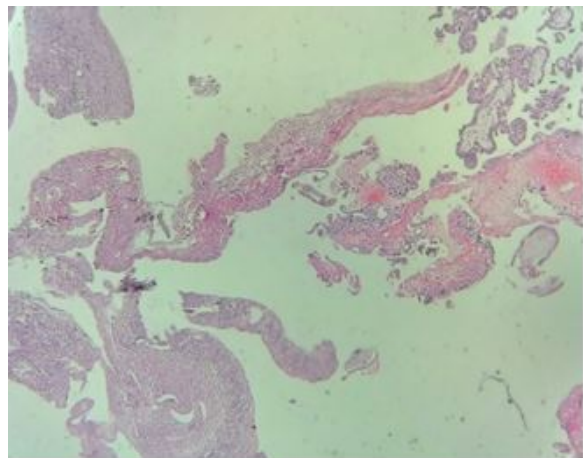
The postop period was uneventful. Histopathology confirmed ovarian pregnancy with villous tissue (Fig 7-9).



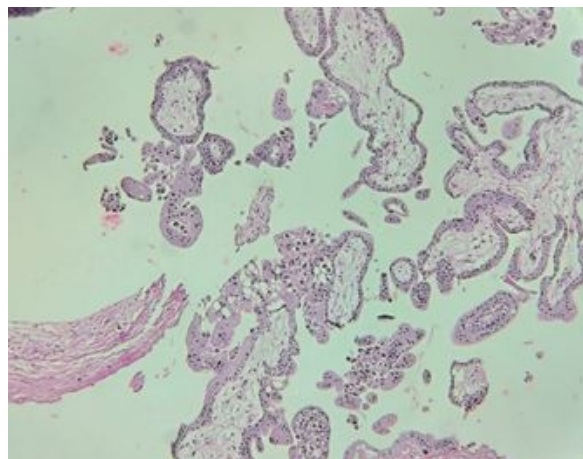
**Figure 1, 2, 3:** Blood in the pelvis, Rt Ovarian pregnancy, Intact Gestational sac & embryo with Ovarian bleeding



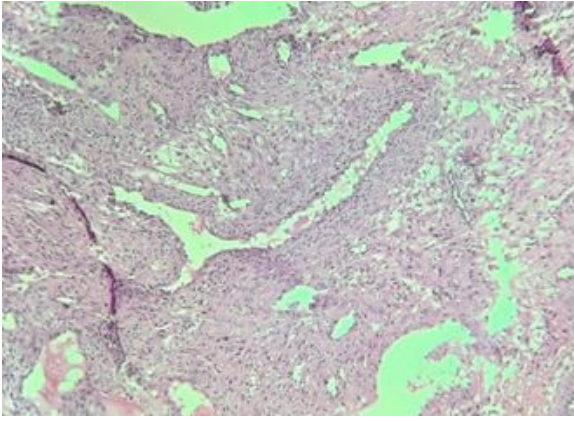
**Figure 4, 5, 6:** Laparoscopic Removal of G. sac, Coagulated bed of Ovarian site & Normal FT



**Figure 7:** Ovarian stroma on the left and chorionic villi on the right.



**Figure 8:** Chorionic villi lined by trophoblasts



**Figure 9:** Decidualized ovarian stroma

## Discussion

The cause of ovarian pregnancy remains obscure and seems to be secondary to the reflux of fertilized oocytes to the ovary [4]. Ovarian pregnancies following IVF, support this theory of reflux [5]. Other hypotheses suggested interference in the release of the ovum from the ruptured follicles, malfunction of fallopian tubes and inflammatory thickening of the tunica albuginea. IUCDs may also be a cause [6].

In the intrafollicular type of ovarian pregnancy, the oocyte is not discharged from the follicle during ovulation, then the sperm enters through the ruptured opening and fertilization occurs in the follicle. In the extrafollicular type, the oocyte is released from the follicle but becomes implanted on the ovarian surface after fertilization [6].

Ovarian pregnancies are categorized into mass formation type or outward development type and correspond to intrafollicular and extrafollicular types [7].

Four **diagnostic criteria** described by Spiegelberg include an ovarian attachment to the uterus by ovarian ligament, intact fallopian tube with its fimbria and separated from the ovary on the affected side, location of a gestational sac in or around the ovary on the affected side and ovarian tissue on histological analysis [8]. However, it is difficult to distinguish between corpus luteal rupture and tubal pregnancy abortion [9]. It does not compromise subsequent fertility [3]. Laparoscopy with conservative treatment is increasingly indicated.

## Conclusion

The diagnosis of ovarian pregnancy is difficult as it presents with similar symptomatology of tubal ectopic pregnancy and hence, continues to be a challenge to diagnose ovarian pregnancy in clinical practice. Laparoscopic excision of ovarian ectopic pregnancy with conservation of the ovary is of utmost importance. Oophorectomy should only be considered in the occurrence of severe uncontrolled bleeding. Ovarian pregnancy does not compromise subsequent fertility.

**Author Contributions:** All authors drafted the article and approved the final version to be published.

## Reference

- Gerin-Lajoie L. Ovarian pregnancy. *Am J Obstet Gynecol.* 1951;62(4):920-929. doi:10.1016/0002-9378(51)90179-2 [Crossref][PubMed][Google Scholar]
- Joseph RJ, Irvine LM. Ovarian ectopic pregnancy: aetiology, diagnosis, and challenges in surgical management. *J Obstet Gynaecol.* 2012;32(5):472-474. doi:10.3109/01443615.2012.673039 [Crossref][PubMed][Google Scholar]
- Kaur N, Reid F, Ma K. Ovarian Ectopic Pregnancy: Laparoscopic Excision and Ovarian Conservation. *J Minim Invasive Gynecol.* 2019;26(6):1006. doi:10.1016/j.jmig.2018.12.017 [Crossref][PubMed][Google Scholar]
- Kraemer B, Kraemer E, Guengoer E, et al. Ovarian ectopic pregnancy: diagnosis, treatment, correlation to Carnegie stage 16 and review based on a clinical case. *Fertil Steril.* 2009;92(1):. doi:10.1016/j.fertnstert.2009.04.014 [Crossref][PubMed][Google Scholar]
- Sergent F, Mauger-Tinlot F, Gravier A, Verspyck E, Marpeau L. Grossesses ovariennes: réévaluation des critères diagnostiques [Ovarian pregnancies: revaluation of diagnostic criteria]. *J Gynecol Obstet Biol Reprod (Paris).* 2002;31(8):741-746. [Crossref][PubMed][Google Scholar]
- Tan K. K. , Yeo O. H. (1968). *Primary ovarian pregnancy. Am. J. Obstet. Gynecol.* 100, 240–249. doi:10.1016/s0002-9378(15)33727-3 [Crossref][PubMed][Google Scholar]

07. Nakagawa K. , Enari T. , Kaneko E. , Kawamura H. , Santou A., Uesato T., et al. (2004). *Ovarian pregnancy: Report of 13 cases in recent ten years.* *Jpn. J. Gynecol. Obstet. Endosc.* 20, 158. doi:10.5180/jsgoe.20.2\_158 [Crossref][PubMed][Google Scholar]

08. Spiegelberg O. Casusistik der ovarialschwangerschaft. *Arch Gynecol.* 1878; 13:73. [Crossref][PubMed][Google Scholar]

09. Ren F, Liu G, Wang T, Li M, Guo Z. Unruptured ovarian ectopic pregnancy: Two case reports and literature review. *Front Physiol.* 2022;13:1036365. Published 2022 Oct 25. doi:10.3389/fphys.2022.1036365 [Crossref][PubMed][Google Scholar]